

**This item is the archived peer-reviewed author-version of:**

Religie: mislukte wetenschap of levenshouding? Een godsdienstfilosofisch strijdpunt

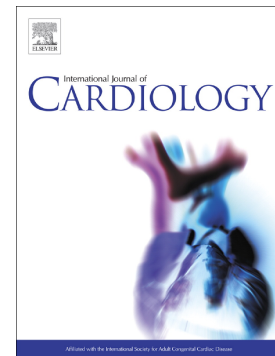
**Reference:**

Van Herck Walter.- Religie: mislukte wetenschap of levenshouding? Een godsdienstfilosofisch strijdpunt  
De uil van Minerva : tijdschrift voor geschiedenis en w ijsbegeerte van de cultuur - ISSN 0772-4381 - 13:3(1997), p. 135-150  
To cite this reference: <https://hdl.handle.net/10067/154970151162165141>

## Accepted Manuscript

Safety of centrifugal left ventricular assist device in patients previously treated with MitraClip system

Enrico Ammirati, Caroline M. Van De Heyning, Francesco Musca, Michela Brambatti, Enrico Perna, Manlio Cipriani, Aldo Cannata, Michele Mondino, Antonella Moreo, Dina De Bock, Victor Pretorius, Marc J. Claeys, Eric D. Adler, Claudio F. Russo, Maria Frigerio



PII: S0167-5273(18)36049-2  
DOI: <https://doi.org/10.1016/j.ijcard.2019.02.039>  
Reference: IJCA 27468  
To appear in: *International Journal of Cardiology*  
Received date: 20 October 2018  
Revised date: 14 January 2019  
Accepted date: 18 February 2019

Please cite this article as: E. Ammirati, C.M. Van De Heyning, F. Musca, et al., Safety of centrifugal left ventricular assist device in patients previously treated with MitraClip system, *International Journal of Cardiology*, <https://doi.org/10.1016/j.ijcard.2019.02.039>

This is a PDF file of an unedited manuscript that has been accepted for publication. As a service to our customers we are providing this early version of the manuscript. The manuscript will undergo copyediting, typesetting, and review of the resulting proof before it is published in its final form. Please note that during the production process errors may be discovered which could affect the content, and all legal disclaimers that apply to the journal pertain.

## Safety of Centrifugal Left Ventricular Assist Device in Patients Previously Treated with MitraClip System

Enrico Ammirati,<sup>1</sup> MD, PhD; Caroline M. Van De Heyning,<sup>2</sup> MD, PhD; Francesco Musca,<sup>1</sup> MD, PhD; Michela Brambatti,<sup>3</sup> MD; Enrico Perna,<sup>1</sup> MD; Manlio Cipriani,<sup>1</sup> MD; Aldo Cannata,<sup>1</sup> MD; Michele Mondino,<sup>1</sup> MD; Antonella Moreo,<sup>1</sup> MD; Dina De Bock,<sup>4</sup> MD; Victor Pretorius,<sup>5</sup> MD; Marc J. Claeys,<sup>2</sup> MD, PhD; Eric D. Adler,<sup>3</sup> MD; Claudio F. Russo,<sup>1</sup> MD; and Maria Frigerio,<sup>1</sup> MD.\*

1 De Gasperis Cardio Center, Niguarda Hospital, Milan, Italy

2 Department of Cardiology, Antwerp University Hospital, Edegem, Belgium

3 Division of Cardiology, Department of Medicine, University of California San Diego, La Jolla, California, USA

4 Department of Cardiac Surgery, Antwerp University Hospital, Edegem, Belgium

5 Division of Cardiothoracic Surgery, University of California San Diego, La Jolla, California, USA

\*The authors take responsibility for all aspects of the reliability and freedom from bias of the data presented and their discussed interpretation

Corresponding Author: Dr. Enrico Ammirati, Niguarda Hospital, Piazza Ospedale Maggiore 3, 20162, Milan, Italy. Phone: +390264447791; email: [enrico.ammirati@ospedaleniguarda.it](mailto:enrico.ammirati@ospedaleniguarda.it)

**ABSTRACT**

**Introduction:** No data regarding the safety of continuous-flow left ventricular assist device (CF-LVAD) implantation in patients with previous MitraClip have been reported. Thus, it remains unknown whether an initial treatment strategy with MitraClip therapy might complicate future heart failure management in patients who are also considered for CF-LVAD.

**Methods:** We retrospectively identified 6 patients (median age of 62 years; 2 women) who had been treated with MitraClip, that were eventually implanted with a CF-LVAD (all Heartware HVAD) in 3 hospitals between 2013 and 2018.

**Results:** Patients were treated in 4 cases with 2 clips, and in 2 cases with 1 clip. Median time from MitraClip implantation to CF-LVAD implant was 282 days (interquartile range 67 to 493), and median time on CF-LVAD support was 401 days (interquartile range 105 to 492 days). Two patients underwent a heart transplant, 3 patients died on support, and 1 is alive on support. In all cases, there was a reduction of functional mitral regurgitation without MitraClip-related complications.

**Conclusions:** Based on this small case series, implantation of a CF-LVAD appears safe in patients with a previously positioned MitraClip system, at least, with 1 or 2 clips in place, with no need for additional mitral valve surgery.

**Key words:** left ventricular assist device; MitraClip; functional mitral regurgitation; heart failure

**Disclosures:** none

## INTRODUCTION

Functional mitral regurgitation (FMR) resulting from functional disruption in the force balance between tethering and closing forces is a common finding in patients with advanced heart failure (HF) and is associated with poor outcome [1]. The MitraClip system, a transcatheter therapy which permanently opposes the anterior and posterior mitral leaflets, is increasingly used in patients with advanced HF and FMR [2]. Even if successful MitraClip treatment can improve symptoms of HF in patients with FMR [3, 4], the underlying cardiomyopathy can progress to refractory HF requiring continuous-flow left ventricular assist device (CF-LVAD) or heart transplant (HTx). In some cases, the MitraClip system is used as an alternative treatment in patients that are already eligible for CF-LVAD to prevent or postpone surgery [5]. Efficacy of percutaneous FMR is still a matter of debate, based on contrasting results of recent clinical trials [5-7]. Furthermore, too much reduction in mitral valve area after MitraClip therapy could be of concern as a potential cause of iatrogenic stenosis. Iatrogenic mitral stenosis could lead to restricting the blood flow into the left ventricle (LV), and decreasing the ability of the CF-LVAD to reduce pulmonary pressures. At present, no data regarding the safety of CF-LVAD implantation in patients with previous MitraClip have been reported. Thus, it remains unknown whether an initial treatment strategy with MitraClip therapy might complicate future HF management in patients who are also considered for CF-LVAD and HTx.

## METHODS

### Study population

We retrospectively identified 6 patients (2 women) who had been treated with MitraClip, that were eventually implanted with a CF-LVAD (all Heartware HVAD) in 2 European hospitals

(Niguarda hospital in Milan, Italy and Antwerp University Hospital in Edegem, Belgium) and 1 US hospital (University of California San Diego, San Diego, California, US) between 2013 and 2018. All patients had FMR at the time of transcatheter mitral-valve repair. Retrospective data were collected in accordance with the local Institutional Review Board.

### **Echocardiography**

Left ventricular ejection fraction (LVEF) and LV volumes were calculated by the Simpson's biplane method. Valvular regurgitation severity was assessed by the integrative approach as recommended [8]. The mitral valve orifice area was measured by planimetry at the level of the mitral valve tips on a short axis view. The mean mitral gradient was obtained by continuous wave Doppler at the tips of the mitral valve leaflets with optimal alignment of the echo beam and the diastolic transmitral flow.

### **Statistical Analysis**

Continuous variables were reported as median and quartile (Q) 1 through Q3. Survival curve was generated according to the Kaplan-Meier method. Software package used was GraphPad Prism (version 6).

## **RESULTS**

Patients (3 with dilated cardiomyopathy and 3 with ischemic cardiomyopathy) were treated in 4 cases with 2 clips, and in 2 cases with 1 clip. At LVAD implantation, median age was 62 years (Q1-Q3: 52 to 65 years), median LVEF was 22% (Q1-Q3: 20 to 23%), and right ventricular (RV) function was preserved or mildly reduced in 5 cases and moderately reduced in 1 case. Median LV end-diastolic diameter (EDD) was 77.5 mm (62.0-84.0 mm) and end-diastolic volume was 286 mL (Q1-Q3: 241-356 mL). All cases had no, or mild aortic regurgitation and tricuspid regurgitation was mild to moderate. Median mitral gradient was 4.0 mmHg (Q1-Q3: 2.8-4.3 mmHg), median valve

area was 3.2 cm<sup>2</sup> (Q1-Q3: 2.9-4.0 cm<sup>2</sup>; data available from 5 patients), and residual or recurrent moderate mitral regurgitation was present in all cases. Median time from MitraClip implantation to CF-LVAD implant was 282 days (interquartile range 67 to 493 days). In 3 cases the surgeon closed the residual atrial septal defect. Median time on CF-LVAD support was 401 days (interquartile range 105 to 492 days). Two patients underwent HTx, 3 patients died on support (1 due to RV failure, 1 due to sepsis, and the other 1 due to intracranial bleeding) and one is alive on LVAD support (**Figure 1** and **Supplemental Figure 1**). No complications related to the MitraClip system were observed. In all cases there was a reduction of FMR severity from moderate to mild mitral regurgitation after CF-LVAD implantation. No clip displacement occurred, although pre-existing partial detachment of one element from the mitral leaflets had been described in 2 patients (in both cases 2 clips were in place) before CF-LVAD implantation. **Figure 2A** shows chest X-ray of a patient supported by a CF-LVAD with 2 clips attached to the mitral leaflets. **Figure 2B** and **Online Videos 1-2** show transesophageal echocardiogram images of a patient treated with 1 clip.

## DISCUSSION

Based on this small case series, implantation of a CF-LVAD appears safe in patients with previously positioned MitraClip system, with no need for additional mitral valve surgery. Thus, the presence of MitraClip does not appear to represent a contraindication or a risk factor for CF-LVAD implantation, at least in the absence of a significant reduction of the mitral valve area as in our experience, where no more than 2 clips were in place. It must be noted that 2 patients were treated with only 1 clip, and 2 out of 4 patients treated with 2 clips had a partial detachment of one clip, potentially explaining the larger mitral valve orifice area (median of 3.2 cm<sup>2</sup>) compared with a previous report (1.9 to 2.8 cm<sup>2</sup>) [9]. In the present case series, LVAD implantation was

performed for advanced HF due to the underlying cardiomyopathy, while FMR was at most moderate after successful MitraClip therapy in all cases. Mitral valve replacement is rarely performed in patients who undergo CF-LVAD implantation. In fact, among 4667 CF-LVAD patients with significant mitral regurgitation reported in the Interagency Registry for Mechanically Assisted Circulatory Support, only 11 patients underwent mitral valve replacement [10]. Patients who underwent combined surgery with mitral valve replacement had a poorer outcome compared with those who did not undergo concurrent mitral valve surgery or those who underwent concurrent mitral valve repair [10]. It must be emphasized that the need for mitral valve replacement cannot be excluded in patients with moderate to severe stenosis after MitraClip therapy (for instance patients with 3 clips, not observed in this series).

The recently published COAPT trial showed that patients with advanced HF and significant FMR can benefit from transcatheter mitral-valve repair resulting in a lower all-cause mortality at 2 years of follow up [5]. In that study, a total of 3 out of 298 patients treated with MitraClip (1.2%) received a LVAD implant during follow up. Nevertheless, no additional data regarding feasibility/safety have been reported [5]. Based on this trial, in the next future, it is expected that a larger number of patients with progression of HF symptoms will undergo CF-LVAD implant despite previous MitraClip therapy. On the other hand, in patients with end-stage dilated HF it remains unclear whether MitraClip has any value as a bridge to HTx or VAD. Of note, the COAPT trial did not include patients with LVEDD >70mm [5], in contrast to the MITRA-FR trial that did not show outcome benefit [6].

Finally, the safety of MitraClip system in patients supported by a CF-LVAD, is further documented by a recent report of a patient on CF-LVAD (Thoratec Heart Mate II) who developed severe FMR, and who was successfully treated with MitraClip [11].



**ACKNOWLEDGEMENT**

This manuscript is dedicated to our dear colleague Dr. Filippo Milazzo, cardiac anesthesiologist from the De Gasperis Cardio Center, Niguarda Hospital in Milano.

**REFERENCES**

1. Bertrand PB, Schwammenthal E, Levine RA, Vandervoort PM. Exercise Dynamics in Secondary Mitral Regurgitation: Pathophysiology and Therapeutic Implications. *Circulation*. 135 (2017) 297-314.
2. Sorajja P, Leon MB, Adams DH, Webb JG, Farivar RS. Transcatheter Therapy for Mitral Regurgitation Clinical Challenges and Potential Solutions. *Circulation*. 136 (2017) 404-17.
3. Van De Heyning CM, Bertrand PB, Debonnaire P, De Maeyer C, Vandervoort PM, Coussement P, et al. Mechanism of Symptomatic Improvement After Percutaneous Therapy for Secondary Mitral Regurgitation: Resting and Exercise Hemodynamics. *J Am Coll Cardiol*. 68 (2016) 128-9
4. Berardini A, Biagini E, Saia F, Stolfo D, Previtali M, Grigioni F, et al. Percutaneous mitral valve repair: The last chance for symptoms improvement in advanced refractory chronic heart failure? *Int J Cardiol*. 228 (2017) 191-7
5. Stone GW, Lindenfeld J, Abraham WT, Kar S, Lim DS, Mishell JM, et al. Transcatheter Mitral-Valve Repair in Patients with Heart Failure. *New Engl J Med*. 379 (2018) 2307-18
6. Obadia JF, Messika-Zeitoun D, Leurent G, lung B, Bonnet G, Piriou N, et al. Percutaneous Repair or Medical Treatment for Secondary Mitral Regurgitation. *N Engl J Med*. 379 (2018) 2297-306
7. Mack MJ, Abraham WT, Lindenfeld J, Bolling SF, Feldman TE, Grayburn PA, et al. Cardiovascular Outcomes Assessment of the MitraClip in Patients with Heart Failure and Secondary Mitral Regurgitation: Design and rationale of the COAPT trial. *Am Heart J*. 205 (2018): 1-11
8. Lancellotti P, Tribouilloy C, Hagendorff A, Popescu BA, Edvardsen T, Pierard LA, et al. Recommendations for the echocardiographic assessment of native valvular regurgitation: an executive summary from the European Association of Cardiovascular Imaging. *Eur Heart J Cardiovasc Imaging*. 14 (2013) 611-44
9. Biaggi P, Felix C, Gruner C, Herzog BA, Hohlfeld S, Gaemperli O, et al. Assessment of mitral valve area during percutaneous mitral valve repair using the MitraClip system: comparison of different echocardiographic methods. *Circ Cardiovasc imaging*. 6 (2013)1032-40
10. Robertson JO, Naftel DC, Myers SL, Tedford RJ, Joseph SM, Kirklin JK, et al. Concomitant mitral valve procedures in patients undergoing implantation of continuous-flow left ventricular assist devices: An INTERMACS database analysis. *J Heart Lung Transplant* 37 (2018) 79-88.
11. Cork DP, Adamson R, Gollapudi R, Dembitsky W, Jaski B. Percutaneous Repair of Postoperative Mitral Regurgitation After Left Ventricular Assist Device Implant. *Ann Thorac Surg*. 105 (2018) e45-e6..

**FIGURE LEGENDS**

**FIGURE 1. Overall survival of patients with MitraClip system and centrifugal left ventricular assist device (CF-LVAD).** Overall survival of patients who initially underwent a percutaneous mitral repair with MitraClip system and later were implanted with a CF-LVAD without replacing the mitral valve. Cases 1, 2 and 6 received a CF-LVAD with a bridge to transplant indication; case 3 as destination therapy and cases 4 and 5 as bridge to candidacy. HTx indicates heart transplant; RV, right ventricular.

**FIGURE 2. Representative diagnostic images of patients who received a centrifugal left ventricular assist device (CF-LVAD) who previously received a MitraClip system.**

**A.** Chest X-ray projections of a patient supported on CF-LVAD treated with 2 clips. **B.**

Transesophageal echocardiogram shows one clip at the level of the mitral valve and the inflow cannula of a CF-LVAD. LVOT indicates left ventricular outflow tract.

## FIGURES

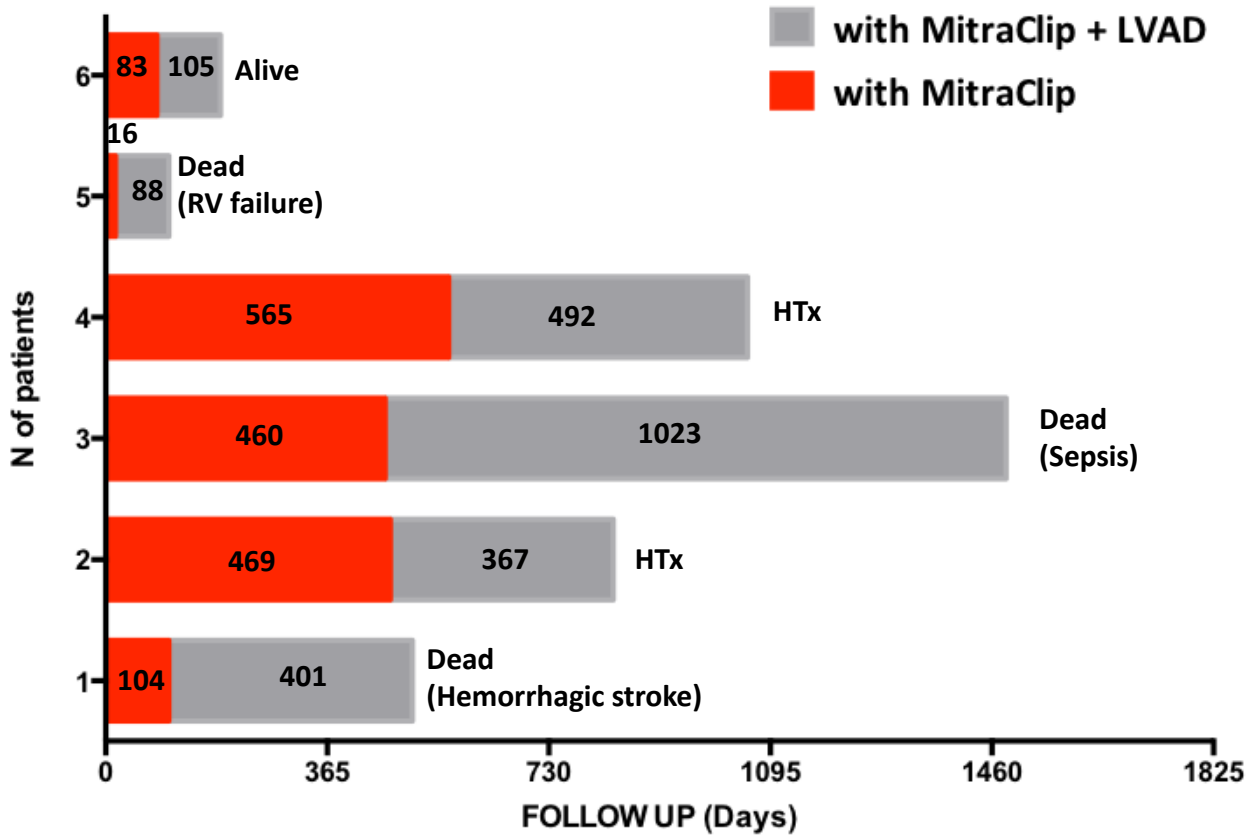


FIGURE 1

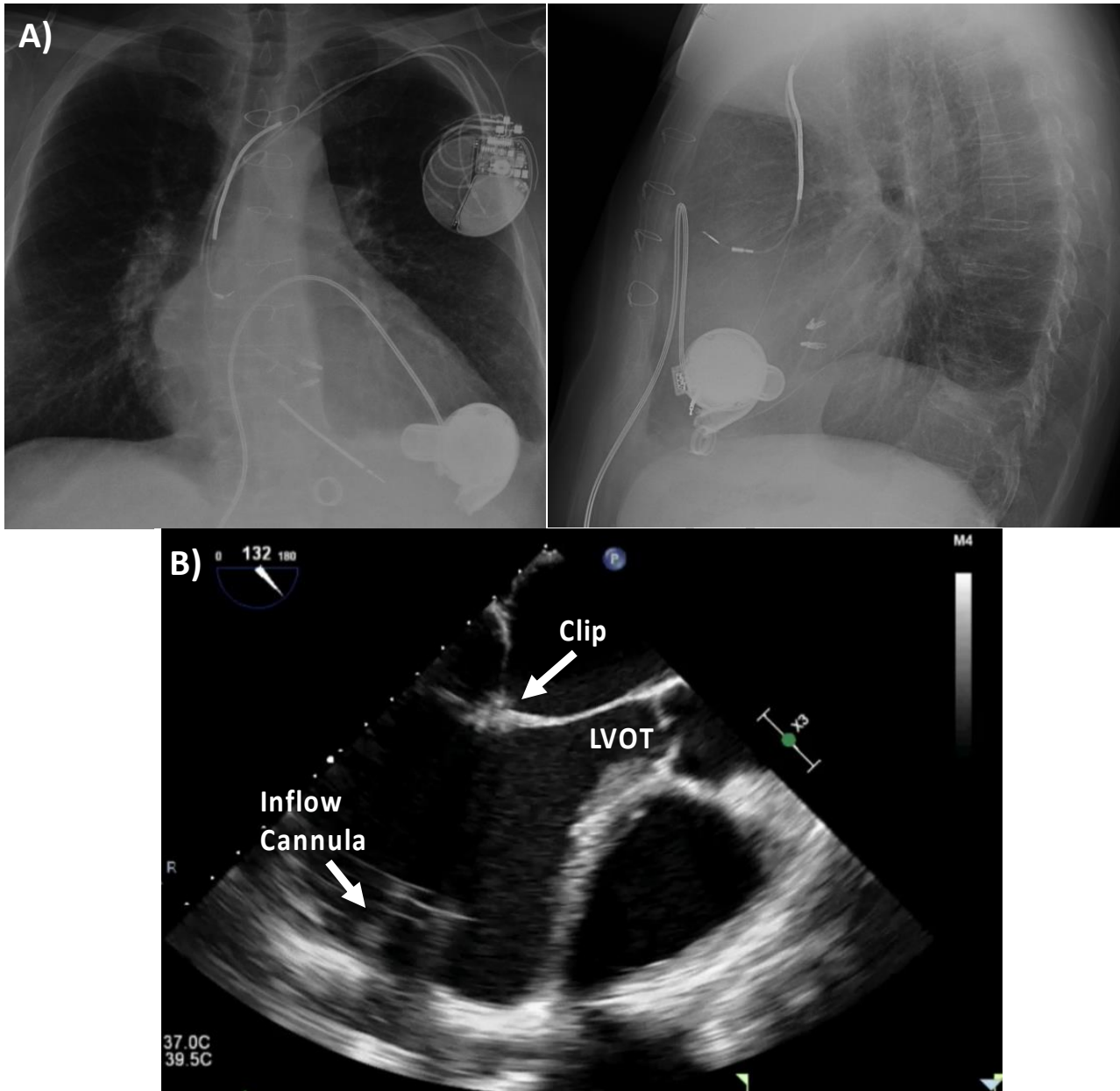


FIGURE 2

**Highlights:**

- No data regarding the safety of continuous-flow left ventricular assist device (CF-LVAD) implantation in patients with previous MitraClip have been reported.
- Based on the present case series of 6 patients, implantation of a continuous-flow left ventricular assist device appears safe in patients with a previously positioned MitraClip system (maximum of 2 clips).

ACCEPTED MANUSCRIPT