

This is an Open Access article licensed under the terms of the Creative Commons Attribution-NonCommercial-NoDerivs 3.0 License ([www.karger.com/OA-license](http://www.karger.com/OA-license)), applicable to the online version of the article only. Distribution for non-commercial purposes only.

# Sinus Sigmoides Thrombosis Secondary to Graves' Disease: A Case Description

Ellen Hermans<sup>a</sup> Peter Mariën<sup>a, b</sup> Peter P. De Deyn<sup>a</sup>

<sup>a</sup>Department of Neurology and Memory Clinic, Middelheim and Hoge Beuken General Hospitals (ZNA), and Reference Center for Biological Markers of Memory Disorders, Laboratory of Neurochemistry and Behavior, Institute Born-Bunge, University of Antwerp, Antwerp, and <sup>b</sup>Department of Clinical Neurolinguistics, Vrije Universiteit Brussel, Brussels, Belgium

## Key Words

Graves' disease · Cerebral venous thrombosis · Subclinical hyperthyroidism · Sinus sigmoides thrombosis

## Abstract

Cerebral venous thrombosis (CVT) is a distinct cerebrovascular condition that represents 0.5–1% of all strokes in the general population. Because of its procoagulant and antifibrinolytic effects [Horne et al.: *J Clin Endocrinol Metab* 2004;89:4469–4473], hyperthyroidism has been proposed as a predisposing factor for CVT [Saposnik et al.: *Stroke* 2011;42:1158–1192]. For the first time, we describe a 22-year-old right-handed woman with a sinus sigmoides thrombosis due to Graves' disease. Although subclinical hyperthyroidism had been detected 2 years before the onset of neurological symptoms, she did not receive any medical follow-up. Early recognition, diagnosis and treatment are of crucial importance, as Graves' disease is a risk factor for CVT and stroke.

## Introduction

Cerebral venous thrombosis (CVT) is a distinct cerebrovascular condition that has an estimated incidence between 0.5 and 1% of all strokes in the general population. It most often occurs in children and young adults, with approximately 5 cases per million individuals annually [2]. Graves' disease represents 50–60% of all hyperthyroidisms and is the most common cause of thyrotoxicosis. It is an autoimmune thyroid disorder with the formation of thyroid-stimulating immunoglobulins that bind to and activate thyrotropine receptors. This process causes growth of the thyroid gland and increases the synthesis of thyroid hormones. The characteristic picture of Graves' disease is a diffusely enlarged

thyroid gland with very high radioactive iodine uptake, excessive thyroid hormone levels and the presence of autoantibodies directed against the thyrotropine receptor [3].

Hyperthyroidism is a predisposing factor for CVT in 1.7% of patients [2]. Indeed, because of its procoagulant and antifibrinolytic effects, hyperthyroidism is a known prothrombotic condition [1, 4] that has been considered an independent risk factor for sinus thrombosis [5]. A thorough review of the literature resulted in 20 case reports describing CVT [5–15] due to hyperthyroidism. Only 8 patients presented Graves' disease with no risk factors other than the use of oral contraceptives and/or elevated factor VIII (F VIII) [9–14].

Here, we describe a unique patient who presented with a sinus sigmoideus thrombosis and an associated venous infarction in the left temporal lobe secondary to Graves' disease.

### Case Report

A 22-year-old right-handed woman was admitted to our hospital because of a generalized tonic-clonic seizure. For 4 days prior to the seizure, she had been complaining of regular headache with vomiting. Palpitations and fatigue had also begun a couple of months earlier. Her medical history consisted of a splenectomy following trauma in 2000 and infectious mononucleosis in 2003. Previous blood tests performed in 2009 by the patient's general practitioner were consistent with subclinical hyperthyroidism characterized by suppressed thyroid stimulating hormone (TSH) ( $<0.01 \mu\text{U/ml}$ ; normal range = 0.30–3.90) with suppressed free T3 (fT3) (3.4 pmol/l; normal range = 4.3–8.1) and normal free T4 (fT4) (11.26 pmol/l; normal range = 10.0–28.2). Notwithstanding these results, the patient was not followed up. Vascular risk factors were limited to the intake of an oral contraceptive containing ethinyl estradiol 0.02 mg and drospirenone 3 mg. There was no history of drug abuse or smoking, and her family history was unremarkable. Preliminary testing on admission revealed the following values: blood pressure 170/70 mm Hg, heart rate 134 beats per minute, eyetone 160 mg/dl and oxygen saturation 100%. During the immediate postictal phase, the patient was agitated and confused. Consciousness was clouded as well. In addition, a neurological examination revealed severe verbal comprehension disturbances. Oral output was limited to indifferent sounds and grunting. The patient presented with automatic behavior consisting of spontaneous eye opening and stereotypical movements of all four limbs. Plantar responses were bilaterally extensor. There was a normal response to pain. There was no nuchal rigidity.

Laboratory results revealed normal blood count, kidney function and liver function. Electrocardiography demonstrated a sinus tachycardia. EEG showed lateralized sharp delta and theta waves with epileptiform discharges in the frontal, temporal and central regions of the left hemisphere. Polyhythmic background activity, mainly consisting of delta waves without epileptiform discharges, was found over the right hemisphere. Based on these findings, a diagnosis of nonconvulsive status epilepticus was made. MRI of the brain showed thrombosis of the left sinus sigmoideus with a secondary venous infarction in the left temporal lobe with hemorrhagic conversion ([fig. 1](#)). Additional thyroid function tests revealed a TSH below  $0.01 \mu\text{U/ml}$ , with an fT3 of 27 pmol/l and an fT4 of 77 pmol/l.

The patient was admitted to the intensive care unit and treatment was started with intravenous (IV) heparin, IV valproic acid 1,500 mg/day, methimazole 60 mg/day, IV contrast 5 ml/day, hydrocortisone 100 mg three times/day and propranolol 40 mg three times/day. After 3 days, her clinical condition gradually improved. When consciousness normalized, fluent aphasia, taxonomically compatible with Wernicke's aphasia, dominated the clinical picture. Speech therapy was initiated and induced a significant improvement of the aphasia.

Laboratory tests for hypercoagulable state were performed before the start of heparin administration. The activities of proteins C and S, antithrombin III, lupus anticoagulants and F V were normal. Additional investigation of the patient's thyroid gland function demonstrated an elevated titer of antithyroglobulin antibodies 250 U/ml (normal:  $<40$ ) and anti-TPO microsomal antibodies 73 U/ml

(normal: <35) with normal TSH receptor antibodies. Thyroid scintigraphy revealed a mildly enlarged, diffusely captating thyroid gland.

A diagnosis of Graves' disease with secondary thrombosis of the left sinus sigmoideus encroaching upon the jugular bulb, associated with a venous infarction in the left temporal lobe, was made.

## Discussion

This patient presented a left sinus sigmoideus thrombosis and secondary stroke due to Graves' disease. Thrombosis of the cerebral veins represents 0.5–1% of all strokes, accounting for approximately 5 cases per million individuals annually. It is more commonly found in young individuals, and hyperthyroidism has been reported to be a predisposing factor for CVT [2].

Hyperthyroidism is a prothrombotic state because of its procoagulant and antifibrinolytic effects [1]. Higher fibrinogen, higher F VIII and plasminogen activator inhibitor-1 and lower protein C is typically found in patients with hyperthyroidism. Since F VIII promotes while protein C inhibits thrombin production, these changes are responsible for hypercoagulability [1]. In addition, there is also a shift towards reduced plasminogen activation, which is responsible for the antifibrinolytic effect [1]. Hyperthyroidism also induces elevation of von Willebrand factor, which is associated with an enhanced platelet function and, therefore, with a shortened clotting time [4].

After carefully reviewing the literature, only 20 case reports dealing with CVT [5–15] due to hyperthyroidism could be found. Only 8 patients had Graves' disease with no risk factors other than the use of oral contraceptives and/or elevated F VIII [9–14]. The latter was only present in 3 patients [13, 14] and was not determined in our patient. In sharp contrast to our patient, the thrombosis did not affect the sinus sigmoideus in these other 8 patients (table 1). The remaining 12 patients either had another etiology of their hyperthyroidism or other thrombophilic risk factors such as factor V Leiden mutations, protein C deficiency, activated protein C resistance, anticardiolipins, plasminogen deficiency, prothrombin G20210A mutation, atrial fibrillation or increased homocysteine with homozygote C6775 polymorphism of the MTHFR gene [5–9]. No causes other than Graves' disease were identified to explain the hypercoagulable state in our patient. Given the known effects of hyperthyroidism on coagulation and platelet function, we believe that this was the sole cause of the thrombosis of the sinus sigmoideus.

Our patient underwent a laboratory test in 2009 which revealed subclinical hyperthyroidism. The definition of subclinical hyperthyroidism is a serum TSH concentration below the statistically defined lower limit of the reference range, with serum fT4 and fT3 concentrations within their reference ranges [16]. When the lower limit of TSH is defined as <0.4 mIU/l, the prevalence of hyperthyroidism is 3.2% [16]. The prevalence of hyperthyroidism decreases to 0.7% at a TSH level <0.1 mIU/l [16]. Each year, 1–2% of patients with subclinical hyperthyroidism and a suppressed TSH level <0.01 µU/ml progress to overt hyperthyroidism [16, 17]. When the serum TSH concentration drops below 0.10 µU/ml, a repeat serum test should be performed within 4 weeks. If TSH levels remain between 0.10 and 0.45 µU/ml, or dip below 0.10 µU/ml, further investigation is required [16, 17]. If further investigations in our patient had been performed during the phase of subclinical hyperthyroidism, early diagnosis and treatment might have prevented the complications of CVT and stroke.

Our patient took an oral contraceptive containing ethinyl estradiol 0.02 mg and drospirenone 3 mg. Ethinyl estradiol is an orally bioactive estrogen. Drospirenone is a synthetic progestin that has antimineralocorticoid properties. The intake of oral contraceptives is linked to an increased risk of venous thrombosis. The use of oral contraceptives is also associated with increased prothrombin, F VII, F VIII, F X, fibrinogen, increased levels of prothrombin fragments 1 and 2, and a decreased F V level, which suggests a procoagulant effect. In addition, there is an acquired resistance to activated protein C, causing a decrease in anticoagulation. This results in a net prothrombotic effect [18]. Recent studies suggest that oral contraceptives containing ethinyl estradiol and drospirenone are associated with a 2- to 3-fold increase in the risk of venous thromboembolism in comparison to second generation oral contraceptives containing levonorgestrel. Although currently considered the preferred choice, oral contraceptives containing levonorgestrel are known to carry a 4-fold increase in the risk of venous thromboembolism in users versus non-users. These studies, however, did not involve patients with sinus thrombosis. Further investigation is required to determine the importance of oral contraceptive use as a risk factor for CVT [19].

### Conclusion

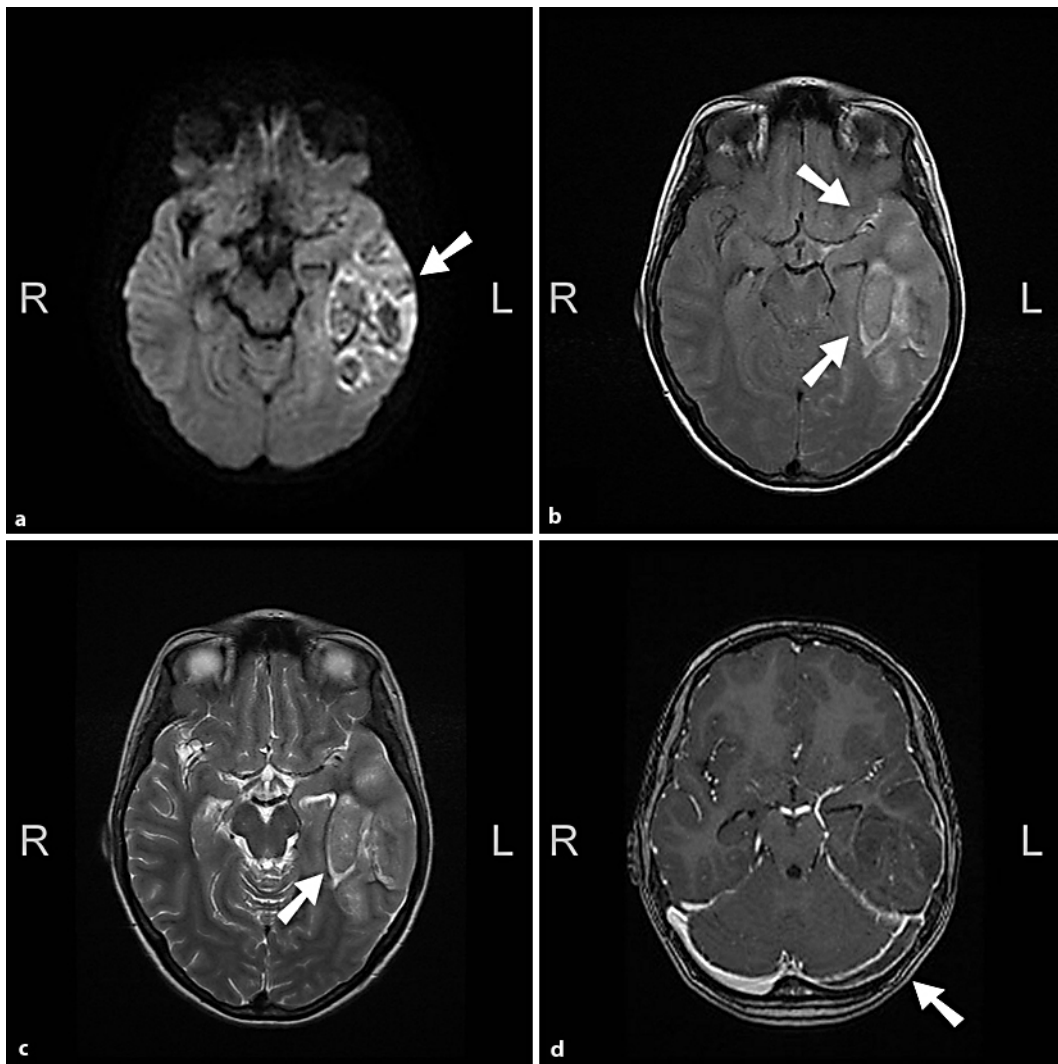
We describe a 22-year-old right-handed female patient with a left sinus sigmoideus thrombosis and secondary infarction in the left temporal lobe as the presenting symptoms of Graves' disease. A concise survey of the literature shows that this localization has not been described before in patients with Graves' disease without other risk factors. Hypercoagulable findings clearly demonstrate the importance of early recognition and follow-up of subclinical and overt hyperthyroidism, since it is a known independent risk factor for sinus thrombosis. Early diagnosis and treatment may prevent serious neurological complications such as CVT and stroke.

### Disclosure Statement

The authors of this work disclose no conflicts of interest.

**Table 1.** Overview of 8 patients with CVT due to hyperthyroidism

Patient	Sex	Age years	Site of thrombosis	Thyroid disease	Other risk factors	Reference
1	M	24	Superior sagittal sinus	Graves' disease	No thrombophilia No atrial fibrillation	10
2	F	32	Superior sagittal sinus Left transverse sinus	Graves' disease	No thrombophilia No atrial fibrillation	10
3	F	18	Deep cerebral veins Inferior sagittal sinus, straight sinus, left lateral sinus	Graves' disease	No thrombophilia, low-dose oral contraceptive pill	11
4	F	38	Left lateral sinus	Graves' disease	No thrombophilia	12
5	F	44	Longitudinal superior sinus, right lateral sinus	Not specified	No protein C or S deficiency	12
6	F	39	Left lateral sinus Left jugular vein	Graves' disease	Oral contraceptive pill Increased F VIII	13
7	F	50	Left parietal cortical vein Left lateral sinus	Graves' disease	Oral contraceptive pill Increased F VIII	14
8	F	38	Superior longitudinal sinus, right lateral sinus	Graves' disease	Oral contraceptive pill Increased F VIII	14



**Fig. 1.** (a–d) Cranial MRI in the axial plane: **a** Diffusion-weighted sequence revealing mixed high- and low-signal lesions indicating ischemic stroke with hemorrhagic transformation. FLAIR (**b**) and FSE T2-weighted images (**c**) showing the venous infarction in the left temporal lobe and the presence of blood in the Sylvian sulcus. **d** Gadolinium-enhanced T1 sequence revealing a complete thrombosis of the left sinus sigmoideus.

## References

- 1 Horne MK, Singh KK, Rosenfeld KG, Wesley R, Skarulis MC, Merryman PK, et al: Is thyroid hormone suppression therapy prothrombotic? *J Clin Endocrinol Metab* 2004;89:4469–4473.
- 2 Saposnik G, Barinagarrementeria F, Brown RD, Bushnell CD, Cucchiara B, Cushman M, et al: Diagnosis and management of cerebral venous thrombosis: a statement for healthcare professionals from the American Heart Association/American Stroke Association. *Stroke* 2011;42:1158–1192.
- 3 Weetman AP: Graves' disease. *N Eng J Med* 2000;343:1236–1248.
- 4 Homoncik M, Gessl A, Ferlitsch A, Jilma B, Vierhapper H: Altered platelet plug formation in hyperthyroidism and hypothyroidism. *J Clin Endocrinol Metab* 2007;92:3006–3012.



- 5 Dai A, Wasay M, Dubey N, Giglio P, Bakshi R: Superior sagittal sinus thrombosis secondary to hyperthyroidism. *J Stroke Cerebrovasc Dis* 2000;9:89–90.
- 6 Nagumo K, Fukushima T, Takahashi H, Sakakibara Y, Kojima S, Akikusa B: Thyroid crisis and protein C deficiency in a case of superior sagittal sinus thrombosis. *Brain Nerve* 2007;59:271–276.
- 7 Kasagu K, Naruse S, Umeda M, Tanaka M, Fujita N: Case of cerebral venous thrombosis due to Graves' disease with increased factor VIII activity (in Japanese). *Rinsho Shinkeigaku* 2006;46:270–273.
- 8 Vaidya B, Coulthard A, Goonetilleke A, Bun DJ, James RA, Kendall-Taylor P: Cerebral venous thrombosis: a late sequel of invasive fibrous thyroiditis. *Thyroid* 1998;8:787–790.
- 9 Squizzato A, Gerdes VE, Brandjes DP, Büller HR, Stam J: Thyroid diseases and cerebrovascular disease. *Stroke* 2005;36:2302–2310.
- 10 Siegert CE, Smelt AH, de Bruin TW: Superior sagittal sinus thrombosis and thyrotoxicosis. Possible association in two cases. *Stroke* 1995;26:496–497.
- 11 Silburn PA, Sandstrom PA, Staples C, Mowat P, Boyle RS: Deep cerebral venous thrombosis presenting as an encephalitic illness. *Postgrad Med J* 1996;72:355–367.
- 12 Karouache A, Mounach J, Bouraza A, Ouahabi H, Reda R, Boutaleb N, Mossadaq R: Cerebral thrombophlebitis revealing hyperthyroidism: two case reports and literature review. *Rev Med Interne* 2004;25:920–923.
- 13 Maes J, Michotte A, Velkeniers B, Stadnik T, Jochmans K: Hyperthyroidism with increased factor VIII procoagulant protein as a predisposing factor for cerebral venous thrombosis. *J Neurol Neurosurg Psychiatry* 2002;73:456–459.
- 14 Mouton S, Nighoghossian N, Berruyer M, Derex L, Philippeau F, Cakmak S, Honnorat J, Hermier M, Trouillas P: Hyperthyroidism and cerebral venous thrombosis. *Eur Neurol* 2005;54:78–80.
- 15 Strada L, Gandolfo C, Del Sette M: Cerebral sinus venous thrombosis in a subject with thyrotoxicosis and MTHFR gene polymorphism. *Neurol Sci* 2008;29:343–345.
- 16 Surks MI, Ortiz E, Daniels GH, Sawin CT, Col NF, Cobin RH, et al: Subclinical thyroid disease: scientific review and guidelines for diagnosis and management. *JAMA* 2004;291:228–237.
- 17 Wilson GR, Curry RW: Subclinical thyroid disease. *Am Fam Physician* 2005;72:1517–1524.
- 18 Vandenbroucke JP, Rosing J, Bloemenkamp KW, Middeldorp S, Helmerhorst FM, Bouma BN, et al: Oral contraceptives and the risk of venous thrombosis. *N Engl J Med* 2001;344:1527–1535.
- 19 Jick SS, Hernandez RK: Risk of non-fatal venous thromboembolism in women using oral contraceptives containing drospirenone compared with women using oral contraceptives containing levonorgestrel: case-control study using United States claims data. *BMJ* 2011;340:d2151.